



PATIENT

Punkin New Hope Dog Rescue

SPECIES

Canine

BREED

Pitbull Terrier Mix

SEX

Female Spayed

AGE

NP

WEIGHT

54.5lbs

INTERPRETED BY

Maggie Machen Lamy, DVM, DACVIM (Cardiology)

IMAGING PERFORMED BY

Cory, DVM

HOSPITAL NAME

Brighton Veterinary Clinic P. C. Inc.

REFERRING VET

Dr. Wade

INVOICE

46573

DATE

1/26/26

PRESENTING CLINICAL SIGNS

History: Garde 3/6 heart murmur. Asymptomatic. Borderline cardiomegaly (VHS: 10.4) on CXR. Today, persistently tachycardic during visit despite fairly calm behavior in clinic.

ECHOCARDIOGRAM FINDINGS

2D, m-mode, color flow and doppler imaging is available. Mild thickening of the mitral valve leaflets with no obvious prolapse into the left atrial lumen. No mitral regurgitation is identified. Normal left atrial dimension. Normal LV diameter with adequate myocardial function. The tricuspid valve appears subjectively normal, with no significant tricuspid regurgitation. The right heart is normal (subjective). No overt evidence of pulmonary arterial hypertension. The pulmonic and aortic valves are normal in morphology and mobility. No aortic abnormalities identified; however, the LVOT velocity is mildly elevated. Normal pulmonic outflow velocities. No aortic or pulmonic insufficiency. No pericardial or pleural effusion noted. No cardiac tumors observed.

CARDIAC CHART

| CANINE CARDIAC PARAMETERS | MR VMAX (m/s) | TR VMAX (m/s) | LA/AO (Boon method) | LA/AO (Heart Base; Swe) | FS (%) | EF (%) | EPSS (cm) |
|---|---------------|---------------|---------------------|-------------------------|---------------------------------|--|--|
| NORMAL PARAMETER | 4.5-5.5 | <2.7 | 1.3 | <1.6 | 28-40 | 40-100 | <0.6 |
| PATIENT | NA | NA | 1.2 | 1.3 | 46 | 78 | 0.2 |
| CANINE CARDIAC PARAMETERS | HR (BPM) | AV VMAX (m/s) | PV MAX (m/s) | BODY WEIGHT (kg) | LA 2D short axis Base view (cm) | LVIDd Avg; 2D and m-mode short axis (cm) | LVIDs Avg; 2D and m-mode short axis (cm) |
| NORMAL PARAMETER | 50-100 | 0.7-1.7 | 0.7-1.6 | BELOW | BELOW | BELOW | BELOW |
| PATIENT | NM | 2.0 | 1.0 | 24.7 | 2.6 | 3.3 | 1.8 |
| *Normal chamber parameters expressed as a mean value (SD) | | | | 3 | 1.27 (5.3) | 2.46 (2.46) | 1.36 (5.5) |
| BODY WEIGHT DEPENDENT PARAMETERS | | | | 5 | 1.40 (4.5) | 2.74 (5.2) | 1.60 (4.7) |
| <i>*Note: All measurements based upon multi-modal images and methods. An average value is reported.</i> | | | | 10 | 1.50 (3.8) | 3.27 (3.5) | 2.06 (3.1) |
| | | | | 15 | 1.83 (2.0) | 3.71 (2.4) | 2.43 (2.1) |
| | | | | 20 | 2.02 (1.9) | 4.14 (2.2) | 2.80 (2.0) |
| Adapted from June Boon, Veterinary Echocardiography, 1998 | | | | 25 | 2.18 (2.4) | 4.48 (2.9) | 3.10 (2.5) |
| Rishniw M and Hollis NE, J Vet Intern Med 2000; 14:429-435 | | | | 30 | 2.33 (3.3) | 4.83 (3.9) | 3.39 (3.4) |
| Hansson et al, Vet Rad and Ultrasound 2002 | | | | 35 | 2.48 (4.3) | 5.17 (5.0) | 3.69 (4.5) |
| Bonagura et al. Echocardiography: principles of interpretation, Vet Clin North Am 15:1177, 1995 | | | | 40 | 2.62 (5.2) | 5.48 (6.1) | 3.96 (5.4) |
| | | | | 50 | 2.88 (7.1) | 6.07 (8.3) | 4.46 (7.4) |

INTERPRETATION OF THE FINDINGS & FURTHER RECOMMENDATIONS

Overtly normal cardiac dimensions and function. The only cause of a murmur identified is increased flow velocity through the LVOT/aortic root. No obvious subaortic narrowing or valvular abnormalities are visualized, and in the absence of structural issues this is considered a benign flow murmur. If the murmur persists or progresses, it is reasonable to monitor periodically via recheck echocardiography in the future. Additionally screening for fluid status abnormalities (dehydration, anemia, etc.) is recommended through routine lab work as volume changes can make this finding more prevalent. No significant valvular insufficiencies were noted and no structural issues identified.

No cardiac medications are indicated. Prognosis is open.



PATIENT

Punkin New Hope Dog
Rescue

SPECIES

Canine

BREED

Pitbull Terrier Mix

SEX

Female Spayed

AGE

NP

WEIGHT

54.5lbs

INTERPRETED BY

Maggie Machen Lamy,
DVM, DACVIM
(Cardiology)

IMAGING PERFORMED BY

Cory, DVM

HOSPITAL NAME

Brighton Veterinary
Clinic P. C. Inc.

REFERRING VET

Dr. Wade

INVOICE

46573

DATE

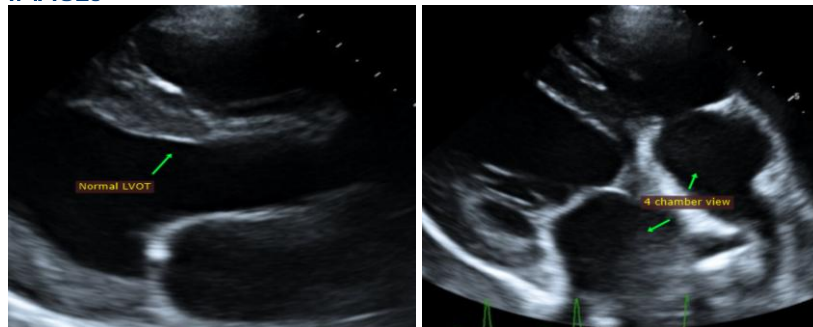
1/26/26

No cardiac contraindication for general anesthesia.

Monitor for any development of cough, labored breathing or exercise intolerance.

Recommend recheck echocardiogram in 12-18 months to screen for development of concurrent cardiac disease that the preexisting murmur may mask.

IMAGES



The information and recommendations provided are based on the images presented by the referring veterinarian. No evaluation can be communicated regarding pathology that was not visible in the image/video clips provided.

Thank you for this referral. This report was generated using transcription software, and minor dictation errors may be present. If the clinical or image interpretation does not parallel your findings or if I can be of any further assistance, please contact me.

Maggie Machen Lamy, DVM
Diplomate of the American College of Veterinary Internal Medicine (Cardiology)
info@sonopath.com